

Problem-Based Learning: A Paradigm Shift in Medical Education

In the realm of medical education, traditional didactic methods are increasingly being complemented or replaced by more interactive and learner-centered approaches. Problem-Based Learning (PBL) stands out as a method that not only enhances knowledge acquisition but also fosters critical thinking, problem-solving skills, and lifelong learning habits among medical students. This essay explores the definition, objectives, and methodology of PBL in the context of medical education.

Definition of Problem-Based Learning

Problem-Based Learning (PBL) is an educational approach that puts students at the center of the learning process. It revolves around the exploration of real-world problems or clinical cases that are relevant to the discipline being studied, such as medicine. Unlike traditional lectures where information is delivered passively, PBL encourages students to actively seek knowledge and construct solutions collaboratively.

Objectives of Problem-Based Learning

The objectives of PBL in medical education are multifaceted and go beyond mere knowledge retention. They include:

1. **Active Learning** : PBL engages students actively in the learning process by presenting them with complex, real-world problems to solve. This fosters curiosity and motivation to explore the subject matter deeply.
2. **Critical Thinking** : By grappling with complex clinical scenarios, students develop critical thinking skills. They learn to analyze information, evaluate evidence, and apply theoretical knowledge to practical situations.
3. **Problem-Solving Skills** : PBL emphasizes the application of knowledge to solve problems. Students learn to identify relevant information, formulate hypotheses, and propose solutions, mirroring the decision-making process in clinical practice.
4. **Collaboration and Communication** : PBL promotes teamwork and communication skills essential for effective healthcare delivery. Students learn to work collaboratively, exchange ideas, and defend their viewpoints—a crucial aspect of interdisciplinary patient care.
5. **Lifelong Learning** : Perhaps most importantly, PBL cultivates a mindset of lifelong learning. By experiencing the challenges of real-world problems, students develop the habit of seeking new knowledge and adapting to evolving medical practices throughout their careers.

Methodology of Problem-Based Learning

The methodology of PBL typically involves the following key elements:

1. **Problem Formulation**: Faculty design or select real-world problems or cases that are complex and relevant to the learning objectives. These problems serve as the foundation for the entire learning process.



2. **Small Group Discussions** : Students work in small groups facilitated by a tutor or facilitator. They analyze the problem, brainstorm ideas, and identify learning issues or knowledge gaps that need to be addressed.
3. **Self-Directed Learning** : Students take responsibility for their learning journey. They independently research topics related to the problem, using textbooks, journals, online resources, and other educational tools to gather information.
4. **Tutor Facilitation** : Tutors guide the learning process without providing direct answers. They facilitate discussions, clarify concepts, and ensure that students stay on track while encouraging critical thinking and exploration.
5. **Synthesis and Application** : After gathering information and exploring possible solutions, students synthesize their findings and apply them to propose solutions or recommendations. This step integrates theoretical knowledge with practical application.
6. **Reflection and Evaluation** : At the conclusion of the PBL session or module, students reflect on their learning experience. They evaluate their understanding of the problem, identify areas of improvement, and discuss how the newfound knowledge can be applied in clinical practice.

Conclusion

Problem-Based Learning (PBL) represents a transformative approach to medical education by prioritizing active learning, critical thinking, and collaboration. By engaging students in authentic clinical scenarios, PBL prepares them not only with knowledge but also with the skills necessary for success in their medical careers. As medical education continues to evolve, PBL remains a cornerstone in producing competent and adaptable healthcare professionals who can meet the challenges of a rapidly changing healthcare landscape.

Betsy

ETSY THOM
FRCOG, DNB, MICO
PRINCIPAL
INSTITUTE OF MEDICAL SCIENCES
AMALA NAGAR, THRISSUR-680



80 year old male admitted with c/o yellowish discolouration of skin and eyes of two weeks duration. He also gives history of pruritus and passing of clay coloured stools.

On examination – afebrile, Pallor ++ , Icterus ++. P/A– Ascites +

Investigations–

Total bilirubin – 10mg/dl

Direct Bilirubin –7.5mg/dl

AST– 35U /L

ALT – 27U/L

Alkaline Phosphatase –1217 U/ml

USG: shows a well defined heterogeneous lesion in the head of pancreas.

Urine -Fouchet's test, Ehrlich's test and Hay's test was done on the urine sample.

Questions

- 1) Interpret the chart and give your diagnosis.
- 2) What would be the likely urine test results in this patient.



20 year old male with history of fever, headache irritability, nausea and fatigue .


O/E febrile, neck stiffness present. LP was done .

Following are the CSF findings -

Pressure	-	Normal
Appearance	-	Clear
Proteins	-	120mg/dl
Glucose	-	60mg/dl
WBC	-	100lymphocytes /mm ³

1. What is your diagnosis ?
2. Name two causative agents for the same?

Betsy



THOMAS
MICOG

MEDICAL SCIENCES
THIRUVANANTHAPURAM-680 555

CHARTS**1. Read the clinical history and answer the following questions**

A 16 year old boy presented to the medical OP with fever, headache, vomiting and neck rigidity. Lumbar puncture was done.

CSF FINDINGS

Appearance	-	White and turbid
Pressure	-	280mm of water
Protein	-	180mg/dl
Sugar	-	10mg/dl
Chloride	-	550mg/dl
Cell count	-	5600 neutrophils/cmm

- 1) *Comment on the chart***
- 2) *What is your diagnosis?***



4 year old child with history of accidental intake of 8 paracetamol tablets. He was admitted to casualty with progressive confusion and abdominal pain.

On examination - yellowish discoloration of sclera ++, right upper quadrant tenderness was demonstrated. Easy bruising noted . Ascitis noted

Investigations

Bilirubin - Total -2.1 mg/dl, Direct Bilirubin – 1.8 mg/ dl

Aspartate aminotransferase (AST) 323 Units/L (Normal 5–40 Units/L)

Alanine aminotransferase (ALT) 358 Units/L (Normal 5–35 Units/L)

Questions

1. What is your diagnosis in this case?
2. What all urine tests will be positive in this case?
3. Mention any other cause for similar kind of jaundice?



20 year old male with history of fever, headache, irritability, nausea and fatigue .

O/E febrile, neck stiffness present. LP was done .

Following are the CSF findings -

Pressure	-	Normal
Appearance	-	Clear
Proteins	-	120mg/dl
Glucose	-	60mg/dl
WBC	-	100lymphocytes /mm ³

1. **What is your diagnosis ?**
2. **Name two causative agents for the same?**



37 year old man presented with anemia, jaundice, splenomegaly & dark urine.

Lab values :

Total Bilirubin - 10 mg/dl

Indirect Bilirubin - 8mg/dl

LDH - 400 U/L (normal 140-2800U/L)

Reticulocyte count - 8%

Osmotic fragility test - Positive.

Fouchet, Ehrlich and Hays tests were done on urine sample.

Questions

1. What is the diagnosis?
2. What would be the likely urine test results in the patient?



80 year old male admitted with complaints of yellowish discolouration of skin and eyes of two weeks duration. He also gives history of pruritus and passing of clay coloured stools.

On examination – afebrile, Pallor ++, Icterus ++. Per abdomen – Ascites +

Investigations–

Total bilirubin – 10mg/dl

Direct Bilirubin –7.5mg/dl

AST– 35U /L

ALT – 27U/L

Alkaline Phosphatase –1217 U/ml

USG: shows a well defined heterogeneous lesion in the head of pancreas.

Urine - Fouchet’s test, Ehrlich’s test and Hay's test was done on the urine sample.

Questions

- 1) Interpret the chart and give your diagnosis.**
- 2) What would be the likely urine test results in this patient.**



40 year old female with diffusely enlarged Thyroid.

<u>Lab Findings</u>	<u>Test Result</u>	<u>Normal values.</u>
TSH	10mu/L	(0.4-5mu/L)
T3	70mg/dL	(80-180mg/dL)
T4	2 μ g/dL	(4.6-12ug/dL)
TPOAb	3.20 IU/ml	(<5.61IU/ml)

1. Comment on the chart
2. What would be your diagnosis if TPOAb is elevated along with above Lab findings.



30 year old man came to the OP with fever and headache

CSF FINDINGS

Appearance standing	-	slightly turbid, cobweb formation on
Pressure	-	250mm of water
Protein	-	100mg/dl
Sugar	-	20mg/dl
Chloride	-	400mg
Cell count	-	500 lymphocytes/cmm

- 1) *Comment on the chart*
- 2) *What is your diagnosis?*



19 year old boy staying at college hostel presented with low-grade fever, nausea, vomiting, loss of appetite, and malaise.

Physical examination - yellowish discoloration of sclera, right upper quadrant tenderness and mild hepatomegaly.

Lab values:

Bilirubin - Total -2.1 mg/dl, Direct Bilirubin – 1.8 mg/ dl

Aspartate aminotransferase (AST) 323 Units/L (Normal 5–40 Units/L)

Alanine aminotransferase (ALT) 358 Units/ (Normal 5–35 Units/L)

HBsAg Negative

Anti-HAV IgM Positive

Anti-HCV antibody - Negative

Alkaline phosphatase (ALP)- 85 Units/mL (Normal 30–115 Units/mL)

Albumin 3.8 mg/dL 3.5–5.5 mg/dL

Glucose 84 mg/dL 70–110 mg/dL.

Fouchet's test, Hay's test and Ehrlich's test were done in the urine sample

- **Interpret the chart and give your diagnosis.**
- **What will be the likely Urine Test results in this patient.**



A 6 year old boy presented with periorbital oedema, hypertension and reddish urine.

He gave a past history of skin infection

Urine examination

Volume in 24 hours	-	600ml
Specific gravity	-	1036
Protein	-	+
RBC	-	+++
RBC cast	-	+++

- 1) ***Comment on the chart***
- 2) ***What is your diagnosis?***



38 year old female with swelling front of neck and heat intolerance, tachycardia and weight loss.

<u>Lab findings</u>	<u>Test result</u>	<u>Normal value</u>
TSH	0.01 mu/L	(0.4-5 mu/L)
T3	200mg/dl	(80-180mg/dl)
T4	14µg/dl	(4.6-12µg/dl)
TPOAb	3.20 lu/ml	(<5.61 lu/ml)

1. Comment on the chart
2. Mention two other associated symptoms
3. Two microscopic findings of this condition.



Bile pigment, bile salt - negative

Broad Waxy casts seen.

Renal ultrasound – Both kidneys are shrunken and illustrate hyper echogenicity and no hydronephrosis seen.

Interpret the chart give your diagnosis.



41 year old male who has a long standing history of hypertension and diabetes and presents with a complaint of pruritis, lethargy, lower extremity edema and emesis.

On physical examination, blood pressure - 180/110. The remainder of exam was unremarkable but for 2+ lower extremity edema and superficial excoriations of his skin from scratching .

Laboratory Data

		Normal values
BUN	170	7-22mg/dl
Creatinine	16.0	0.7-1.5mg/dl
Alkaline Phosphatase	306	30-110IU/L
Parathyroid Hormone	895	10-65 pg/ml
Hemoglobin	8.6	14-17gm/dl
Mean cell volume	88	85-95FL

Urinalysis

pH - 6.0

Specific gravity - 1.010

Protein - 1+

Glucose - negative

Acetone - negative

Occult blood - negative



A 60 year old business man felt severe chest pain in the morning that was radiating to the medial aspect of his left upper arm. There was also profuse sweating and breathlessness. The patient is a known diabetic.

O/E-Diaphoresis noted, he was anxious

Pulse rate -100/minute, BP-98/64mm of Hg

His ECG recordings show ST elevation and T inversion.

Questions

- 1. What is your diagnosis?**
- 2. What are the other serum markers that will be raised?.**
- 3. Draw a graphical representation of the variation of the different enzyme levels with time.**



Read the clinical history and answer the following questions

A 5 year old child presented at the pediatric OP with generalized oedema

Urine examination

24 hour urine volume	- 1200ml
Specific gravity	- 1030
Protein	- +++++
RBC	- Nil
RBC cast	- Nil
Granular cast	- ++

1. **Comment on the chart**
2. **What is your diagnosis?**



Total sperm count -150 million/ul (Normal 60-150million/ul)

Microscopic examination:

Morphology of sperm:

Normal -35%

Abnormal -65%

- 1. Interpret the report & give your diagnosis.**
- 2. Enumerate the abnormal morphological forms of sperm.**



A couple seeking medical attention for infertility 5 years post marriage was investigated. Husband is a 40 yr old smoker. Semen analysis was done and reported as follows:

Sample collection : **In laboratory**

Time of ejaculation : **10:15am**

Period of abstinence : **5 days**

Physical examination :

Volume	- 4ml
Colour	- White
Appearance	- Opulence
Consistency	- viscous
Odour	-Musty
Coagulation/mucus/pus/blood	- Not found

Chemical examinations:

pH	-7.5
Fructose	-present (normal -150-600mg/dl)

Study of motility :

After liquefaction	-70% motile
Progressive movement	- 55%
Moderate movement	-35%
Poor movement	-10%



Total sperm count

- 5 million / ul (Normal 60-150million/ul)

Microscopic examination

Morphology of sperm

-Normal -65%

-Abnormal -35%

- 1. Interpret the report & give your diagnosis.**
- 2. List the various sperm count abnormalities.**
- 3. Define Necrospemia .**



A couple seeking medical attention for infertility after 5 years of marriage was worked up in the clinic. Husband a smoker and alcoholic, aged 34 years .Semen analysis was done & reported as follows:

Sample collection : **In laboratory**

Time of ejaculation : **10:15am**

Period of abstinence : **5 days**

Physical examination:

Volume	-0.5ml
Colour	- White
Appearance	- Opalescent
Consistency	- viscous
Odour	-Musty
Coagulation/mucus/pus/blood	- Not found
Liquefaction time	- 20mins

Chemical examination:

pH	- 7.5
Fructose	-100mg/dl (normal -150-600mg/dl)

Study of motility:

After liquefaction	-30% motile
Projective movement	- 15%
Moderate movement	-15%
Poor movement	-70%

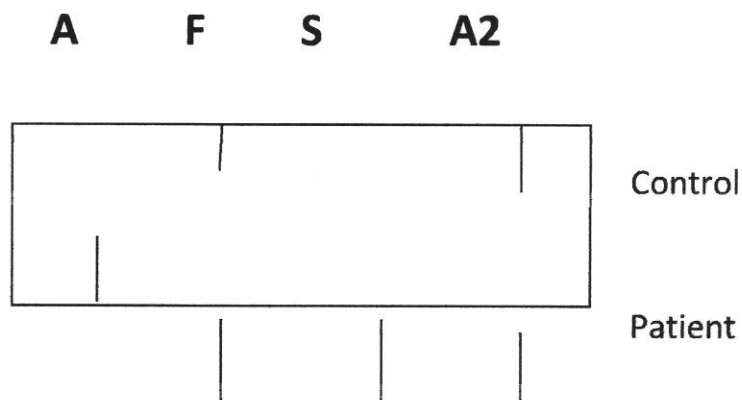


18 year old tribal girl was admitted with severe abdominal pain. She had severe pallor on examination.

INVESTIGATION RESULTS

Hb -9g%
Reticulocyte count - 14%

Hemoglobin electrophoresis strip



- 1) ***What is your diagnosis?***
- 2) ***What other tests are available for this disease?***



A 30 year old female presented with complaints of tenderness and swelling of knee and elbow joints. She also had rash over her malar eminences. ANA profile was done and ds-DNA was found to be positive. Few months later she presented to the emergency department with fatigue and breathlessness.

On examination- Pallor ++, Icterus ++

Hemogram : Hb-5gm/dl, TC-6000 /mm³,

Differential Count -N₇₀ L₂₈ M₁ E₁

Platelet count - 2lakh/ mm³

Reticulocyte count - 12%

Direct Coomb's Test is positive.

1. ***What is your diagnosis?***
2. ***Describe the peripheral smear picture in this condition .***



34 year old female presented with anaemia, jaundice& moderate splenomegaly.

INVESTIGATION RESULT

Hb	-	9g/dl
MCV	-	70 fl
MCHC	-	35%
Osmotic fragility	-	increased

- 1) *What is your diagnosis?*
- 2) *What will be the peripheral smear picture?*



8 year old boy was admitted with severe pallor and hepatomegaly.

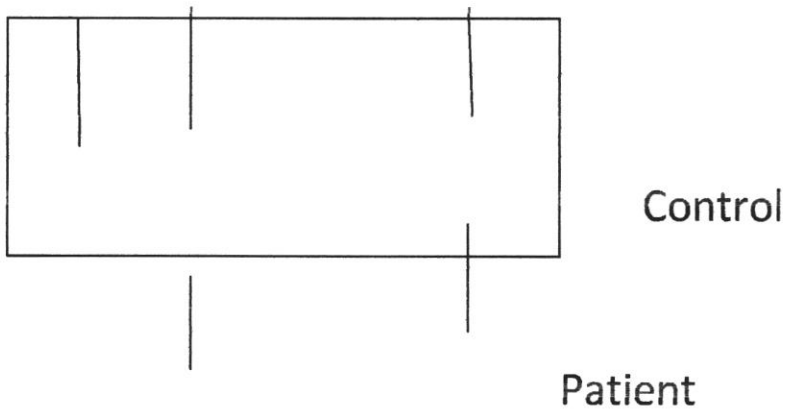
INVESTIGATION RESULTS

Hb - 6g%

Reticulocyte count - 12%

Peripheral smear - hypochromic microcytic anaemia

A F S A2



- 1) ***What is your diagnosis?***
- 2) ***What other tests are available for this disease?***

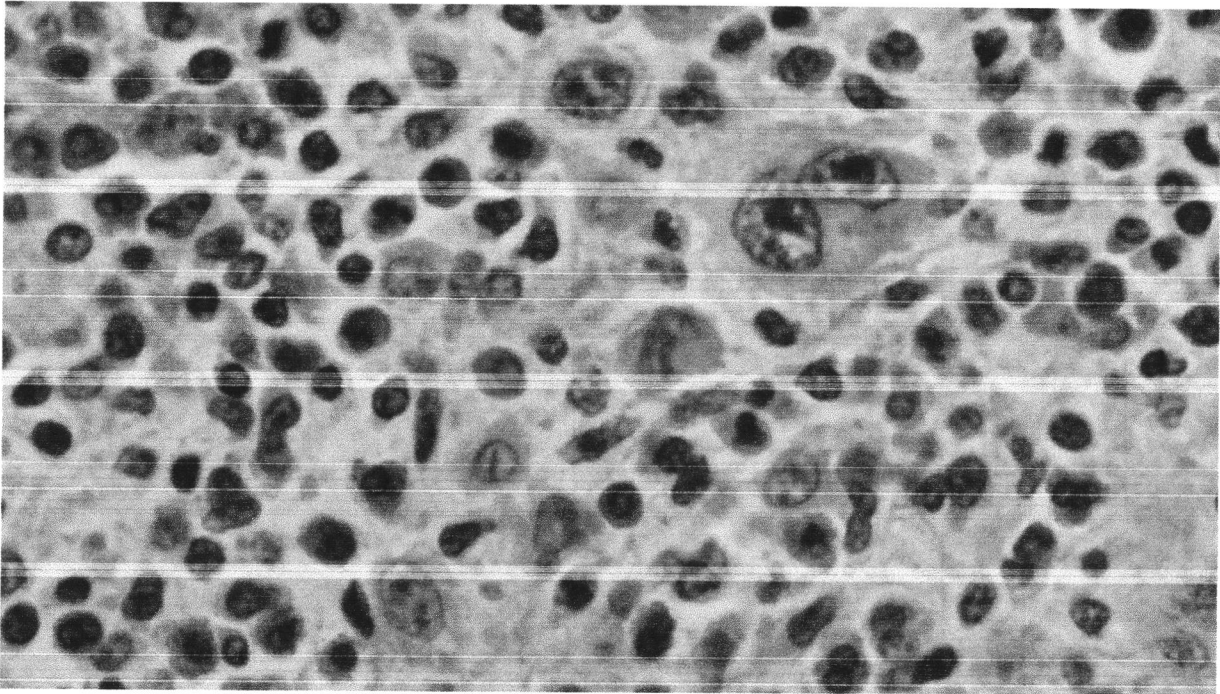


12 year old girl came with painless swelling neck. She also had cough and shortness of breath.

O/E a single upper cervical node measuring 3 cm was palpated with rubbery consistency.

Radiologic studies showed mediastinal lymphadenopathy.

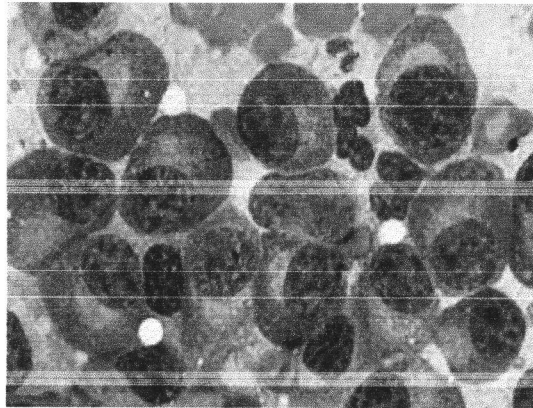
Microscopic picture was as shown below:



1. What is your diagnosis?
2. List two characteristic microscopic features of this condition.



60 year old man came to orthopedic OPD with back pain. His routine blood examination showed a HB value of 8g/dL and an ESR of 120mm/1st hour. Total WBC count, differential count and platelet count were normal. A bone marrow aspiration was done and the microscopic picture is given below:



1. What is your diagnosis?
2. What is the likely skeletal X-ray findings in this patient
3. Mention two other investigations done in this condition.



12 year old female child was admitted to the paediatrics unit with history of nose bleeds. O/E petechiae were seen on legs and arms.

INVESTIGATION RESULTS

Bleeding time	-	12min
Clotting time	-	6min
Platelet count	-	$40 \times 10^9/L$
PT	-	14 sec
APTT	-	34sec
FDP	-	$<5 \mu\text{gm/ml}$

- 1) *What is your diagnosis?***
- 2) *What will be the bone marrow picture?***

A 12 year old male child was admitted with history of prolonged bleeding after minor injuries. He also has Haemarthroses involving right knee joint.

INVESTIGATION RESULTS

Bleeding time	-	3 min
Clotting time	-	26 min
Platelet count	-	$240 \times 10^9/L$
PT	-	14 sec
APTT	-	66 sec
FDP	-	$<5 \mu\text{gm/ml}$

- 1) *What is your probable diagnosis?*
- 2) *What are the clinical sequelae of this disorder?*



12 year old female child was admitted to the paediatrics unit with history of nose bleeds. O/E petechiae were seen on legs and arms.

INVESTIGATION RESULTS

Bleeding time	-	12min
Clotting time	-	6min
Platelet count	-	$40 \times 10^9/L$
PT	-	14 sec
APTT	-	34sec
FDP	-	$<5 \mu\text{gm/ml}$

- 1) *What is your diagnosis?***
- 2) *What will be the bone marrow picture?***

24 year old lady with history of snake bite was admitted for treatment. The patient developed bleeding from gums and purpuric spots in the skin. Hematuria was noticed. There were features of multi organ failure.

Investigations

PT	-	22sec. (11-16sec)
APTT	-	62sec. (22.6-35 sec)
THROMBIN TIME	-	30sec. (20sec)
FIBRINOGEN	-	70mg/dl (140-400mg/dl)
PLATELET COUNT	-	50,000cells/mm ³ (1.5 -4Lakhs)
FIBRIN SPLIT PRODUCTS	-	100mcg/ml (<10mcg/ml)
D-DIMER	-	elevated >1000g/L (<0.5g/L)
PERIPHERAL SMEAR	-	fragmented red blood cells seen

Questions –

What is your diagnosis?

What are the other causes for this condition.



Betsy

Dr. BETSY THOMAS
MD, FRCGS, DNB, MCOG
PRINCIPAL
AMALA INSTITUTE OF MEDICAL SCIENCES
AMALA NAGAR, THRISUR-680 555

6)PBL material prepared by teachers

MBBS PHASE III PART 2 2019 BATCH CASE BASED DISCUSSION

PART 1

45 years old man develops progressive breathlessness and swelling of both the feet. On examination respiratory rate was of 22/mt, heart rate of 96/mt. and BP 100/70 mm of hg. JVP raised 14cms and both a and v waves were seen. On auscultation 3rd heart sound and bilateral fine crepitation were present. Liver was palpable 3cms below costal margin. There is no free fluid in the abdomen.

- A. What is your probable diagnosis? Enumerate points in favour of your diagnosis
- B. How do you stage this condition?
- C. Enumerate the causes of unilateral and bilateral lower limb edema

PART 2

- A. Define JVP . Draw and label the waves of JVP
- B. Enumerate the abnormalities in JVP and the conditions in which they are seen

PART 3

- A. Mention the physiology and causes of third heart sound.
- B. How do you investigate this patient ?

PART 4

- A. Define Pulse. Draw and label arterial pulse
- B. Enumerate the variations in volume and character of arterial pulse

OSCE STATION-CHARTS

1. 25 year old female presented with fever, malar rash, photosensitivity , oral ulcers and polyarthralgia of two months duration. She gives history of two 1st trimester abortions.

1. What is your diagnosis? – 4 marks
2. Mention four drugs used in the treatment of this condition.-4 marks

2. 50 yr old male known case of chronic liver disease presents with high grade fever with chills and abdominal distension of 2 days duration

Ascitis fluid study shows

TC -525 cells.

DC- Neutrophils 256 Lymphocytes. 279

Protein = 2 mg%.

- 1) What is your diagnosis? – 4 marks
- 2) Mention two drugs used to treat this condition?- 2 marks

Mention drug used for prophylaxis - 2 marks

3. 20 yr old male migrant from Mumbai presents with high grade fever, altered sensorium and purpuric rashes of 4 days duration. Peripheral smear clinched the diagnosis

What is your diagnosis. – 4 marks

- 1) Mention two differential diagnosis. – 2 marks
- 2) Mention two differential diagnosis. – 2 marks
- 3) Enumerate the drugs used in the condition?- 2 mark

4. CSF Report :-

Appearance: clear with cobweb formation

TC – 150 cells.

DC- Polymorph 10 Lymph 90

Protein- 300mg/dl

Sugar-96 mg/dl

Corresponding blood sugar – 150 mg/dl

- 1) What is your diagnosis? - 2 marks
- 2) Mention two neurological complications of this disease - 2 marks
- 3) Mention 4 drugs used to treat this condition. - 4 marks

5. 65 yrs male, with history of body pain and fracture right femur following minor trauma;

Hb: 6.7 g%, TLC : 8300/mm³, ESR : 113mm in 1st hr

Total protein : 6.5 /dl, S. Albumin : 2.8 g%, S. globulin : 3.7 g%

X ray skull : ? lytic lesion



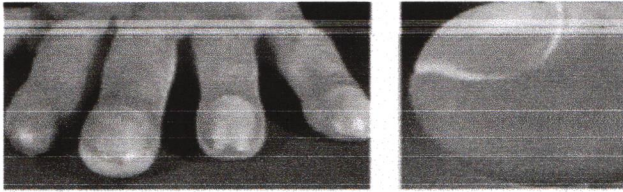
S. electrophoresis : prominent spike in γ globulin region.

1. What is your diagnosis? – 4 marks
2. Mention 2 complications of this condition – 2 marks

Mention 2 drugs used in treatment – 2 marks

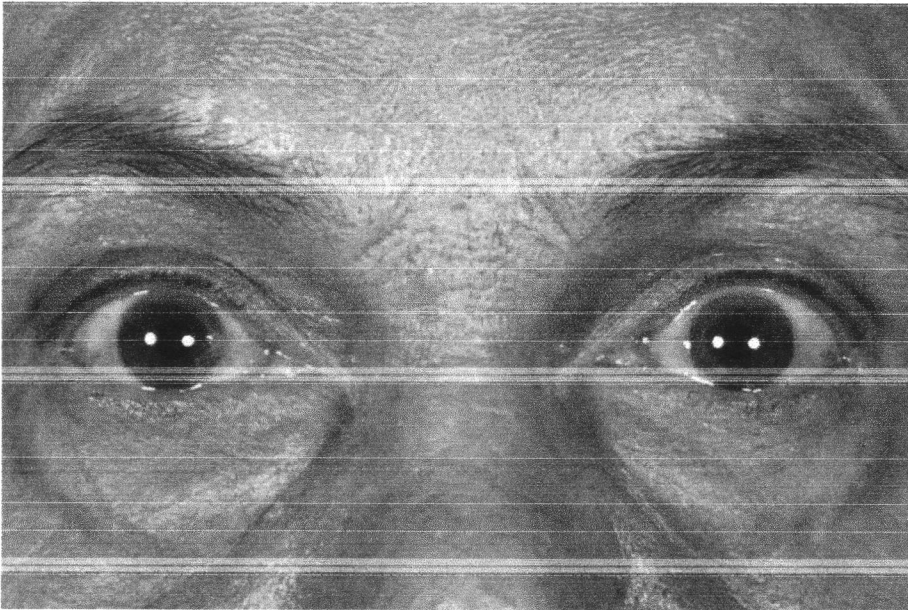
OSCE STATION 3

52 year old smoker presented to you with complaints of blood in sputum. On examination you find this.



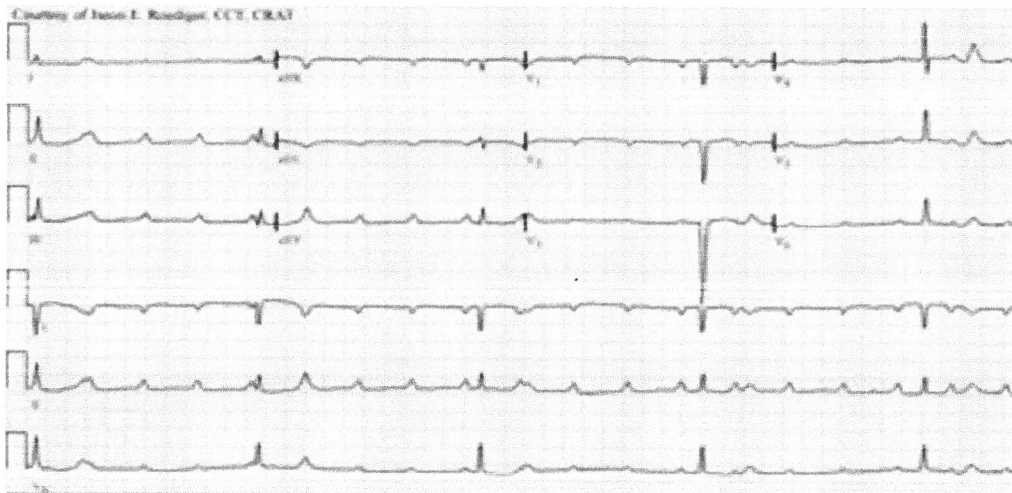
- a) What is the clinical sign seen? (4)
- b) Mention four causes for this clinical sign (4)






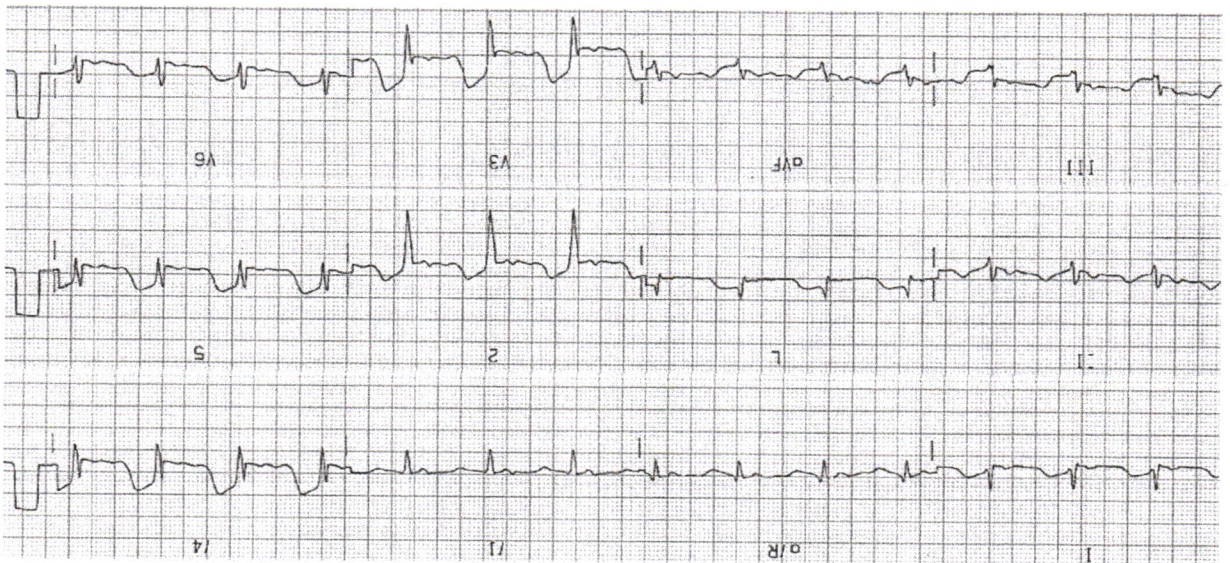
- a) What is the clinical sign seen here? (2)
- b) Mention the three types associated with this sign? (2)
- c) Mention four causes for this clinical sign? (4)

60 year old female with history of recurrent episodes of syncope

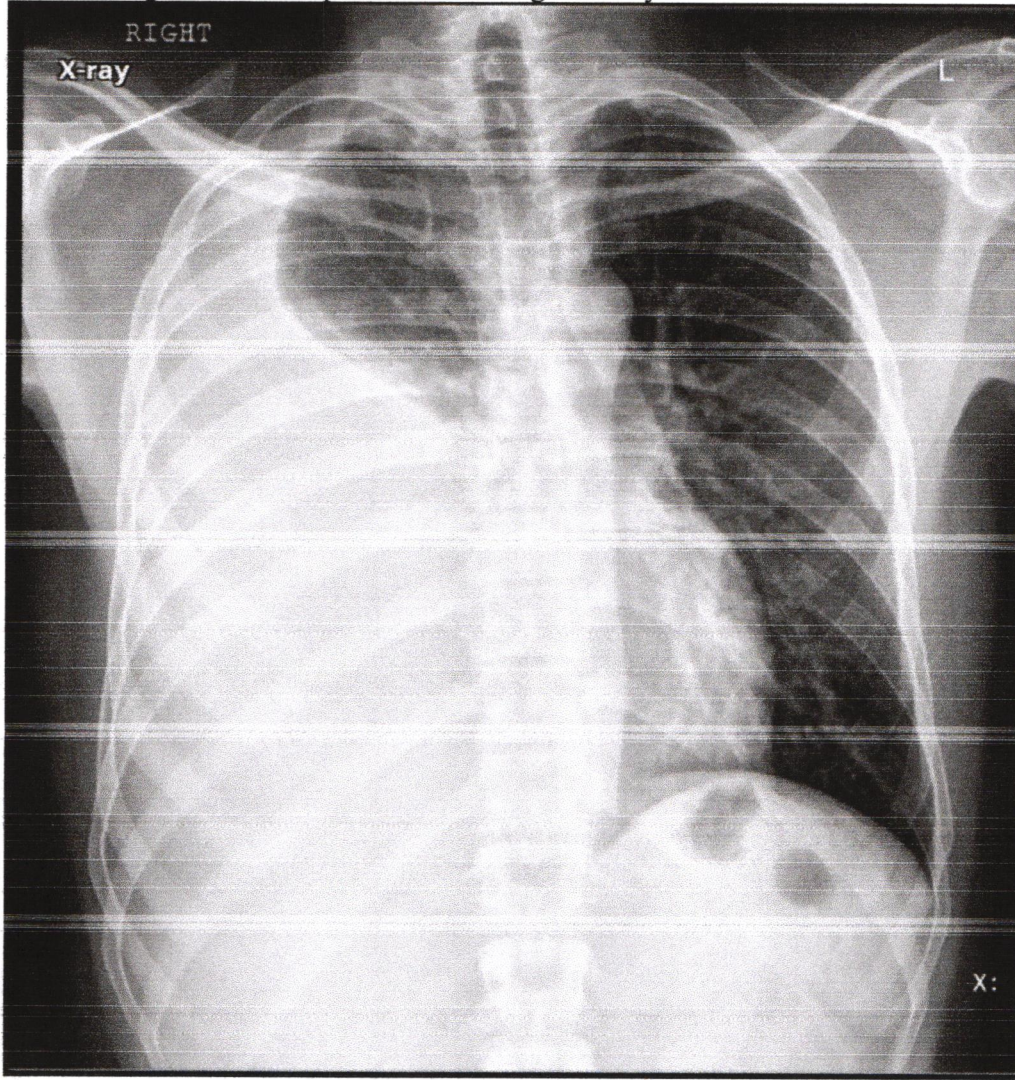


55 year old male, diabetic with acute onset central chest pain, radiating to left arm and jaw associated with profuse sweating and breathlessness.





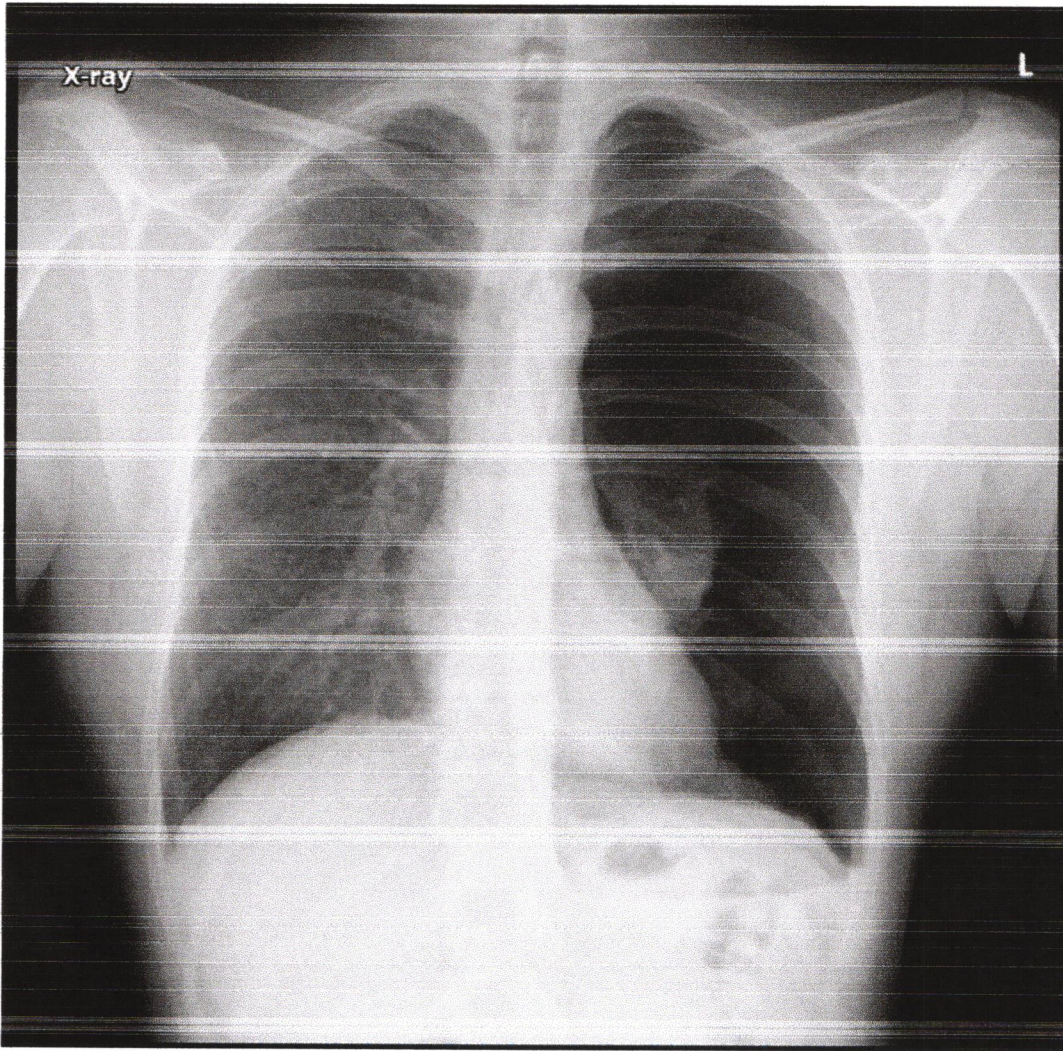
40yr male came with right-sided chest pain with breathing difficulty.



Betsy

Dr. BETSY THOMAS
MD, FRCOG, DNB, MICOG
PRINCIPAL
AMALA INSTITUTE OF MEDICAL SCIENCES
AMALA NAGAR, THRISSUR-680 555

68yr male smoker came with odd episodes of cough and acute onset breathing difficulty



Betsy



Dr. BETSY THOMAS

M.D., F.R.C.S., D.N.B., M.I.C.O.G.

PRINCIPAL

AMALA INSTITUTE OF MEDICAL SCIENCES

AMALA NAGAR, THRISSUR-680 555