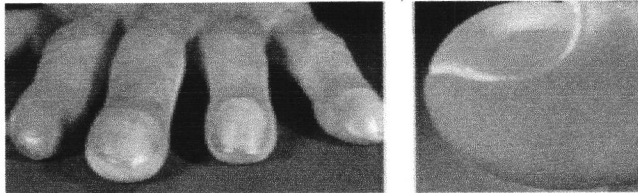




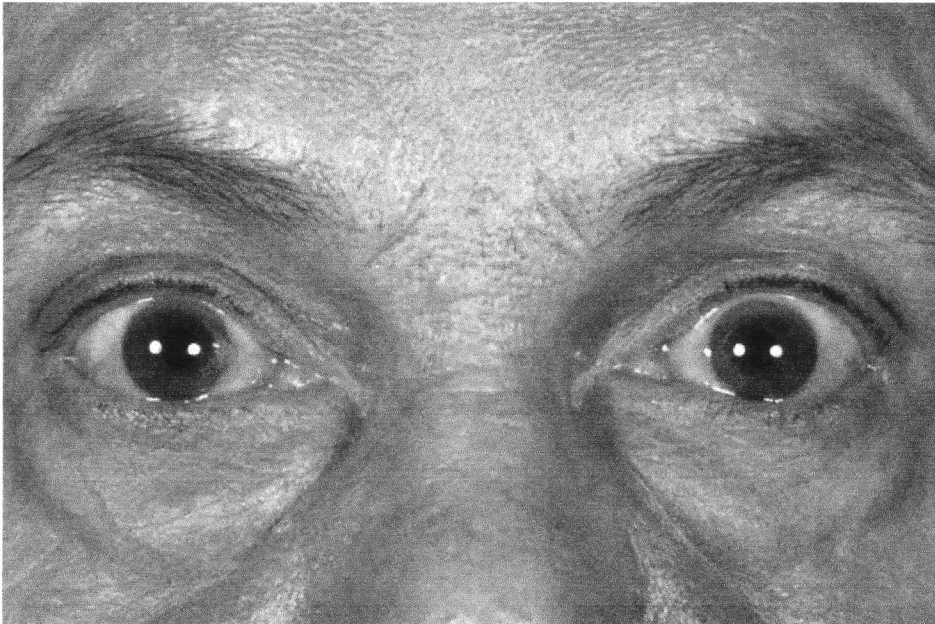OSCE STATION 3

52 year old smoker presented to you with complaints of blood in sputum. On examination you find this.



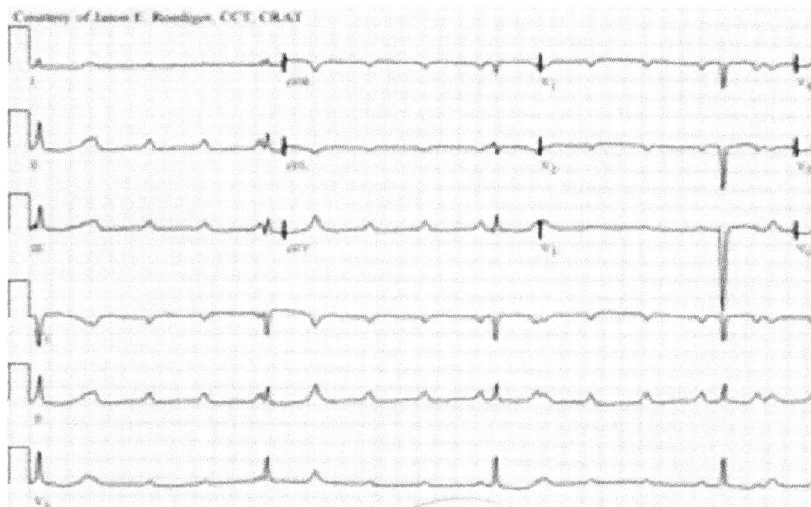
- a) What is the clinical sign seen? (4)
b) Mention four causes for this clinical sign (4)





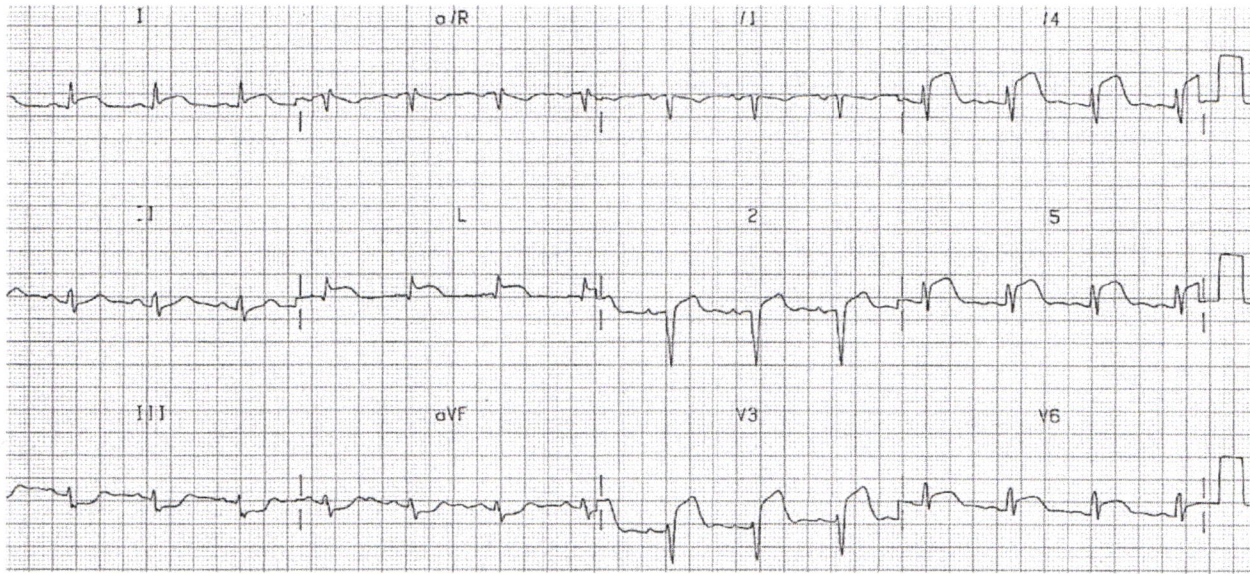
- a) What is the clinical sign seen here? (2)
- b) Mention the three types associated with this sign? (2)
- c) Mention four causes for this clinical sign? (4)

60 year old female with history of recurrent episodes of syncope





55 year old male, diabetic with acute onset central chest pain, radiating to left arm and jaw associated with profuse sweating and breathlessness.



Betsy

Dr. BETSY THOMAS
MD, FRCOG, DNB, MICO
PRINCIPAL
AMALA INSTITUTE OF MEDICAL SCIENCES
AMALA NAGAR, THRISSUR-680 555



OSCE STATION- AETCOM

1. Patient diagnosed to have T2DM needs to be initiated on OADs. However patient is concerned about renal failure as a possible side effect from medication. How would you want to counsel this patient?
2. Patient with bronchial asthma is discharged after being treated for an acute exacerbation. Patient is being sent home on MDI. How would you educate regarding the use of the same?
3. Patient recent diagnosed to have atrial fibrillation. Patient is going to be started on anticoagulant warfarin. Educate regarding the drug.
4. Patient has been diagnosed to have T2DM. Patient has been initiated on medication. How would you counsel regarding lifestyle modification?

7).Faculties received training on PBL

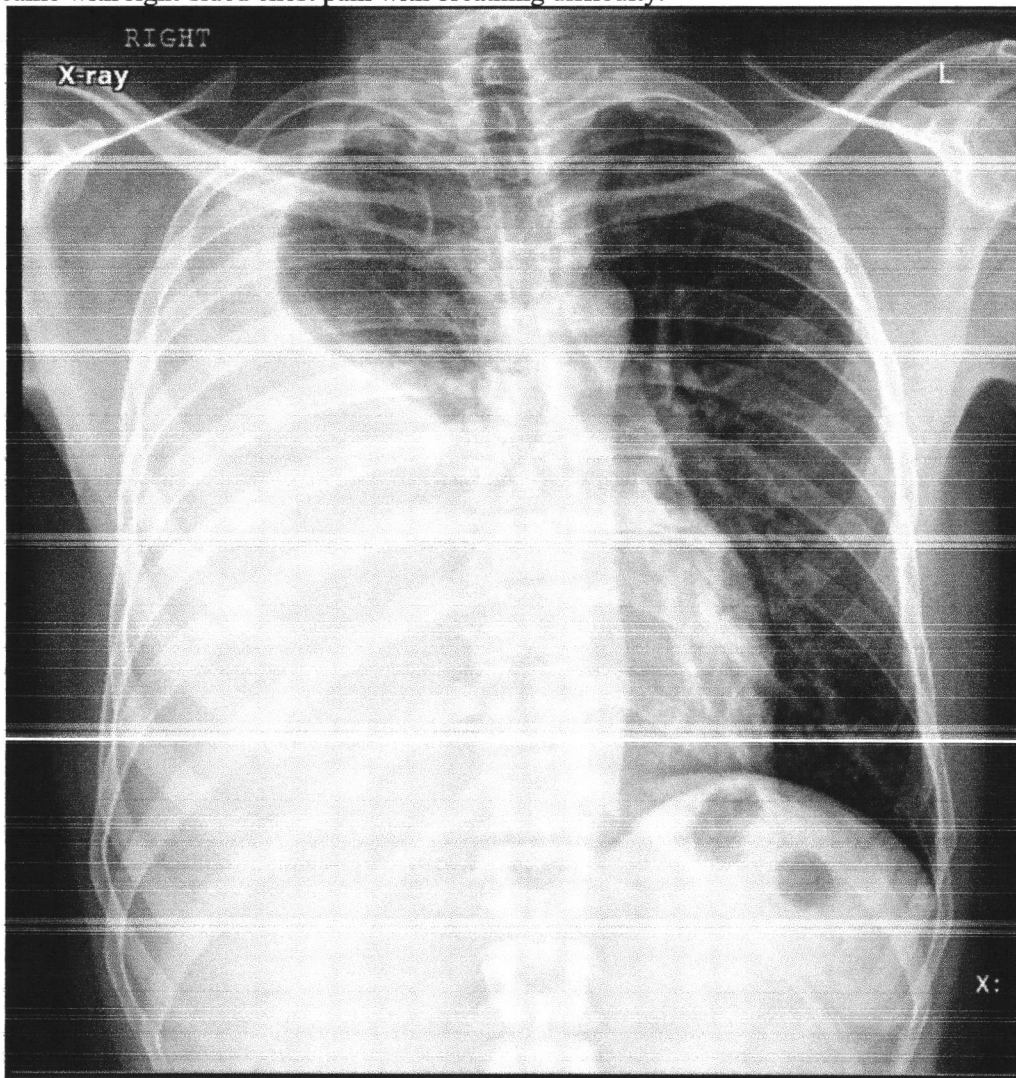
Dr.S.Narayanan Potty

Dr.Edwin J George

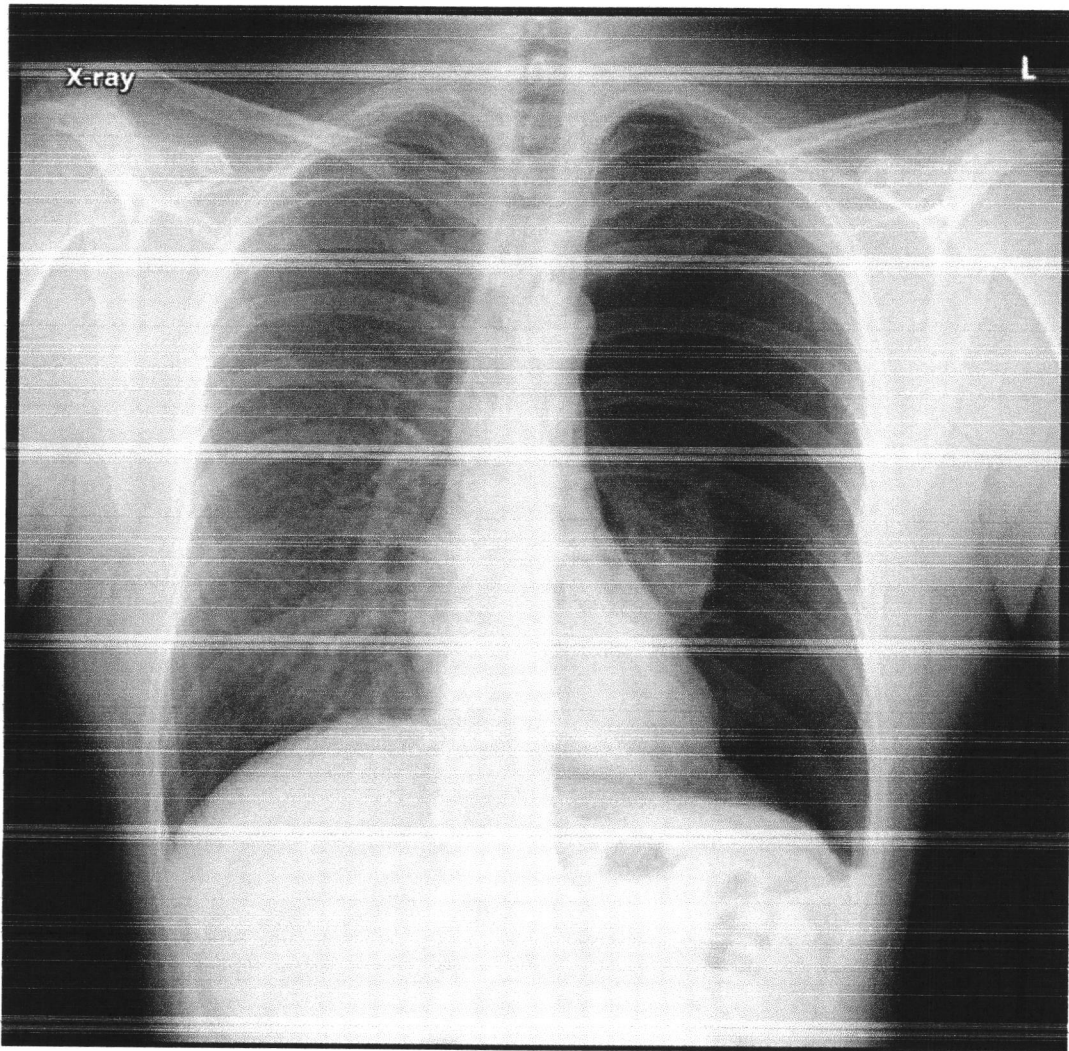
Dr.Anish S



40yr male came with right-sided chest pain with breathing difficulty.



68yr male smoker came with odd episodes of cough and acute onset breathing difficulty



OSCE STATION- AETCOM

1. Patient diagnosed to have T2DM needs to be initiated on OADs. However patient is concerned about renal failure as a possible side effect from medication. How would you want to counsel this patient?
2. Patient with bronchial asthma is discharged after being treated for an acute exacerbation. Patient is being sent home on MDI. How would you educate regarding the use of the same?
3. Patient recent diagnosed to have atrial fibrillation. Patient is going to be started on anticoagulant warfarin. Educate regarding the drug.
4. Patient has been diagnosed to have T2DM. Patient has been initiated on medication. How would you counsel regarding lifestyle modification?

7).Faculties received training on PBL

Dr.S.Narayanan Potty

Dr.Edwin J George

Dr.Anish S



Betsy

Dr. BETSY THOMAS
MD, FRCOG, DNB, MICOG
PRINCIPAL
AMALA INSTITUTE OF MEDICAL SCIENCES
AMALA NAGAR, THRISSUR-680 555