

VOLUME - 1 | ISSUE - 1 | APRIL 2024



# Amala


INSTITUTE OF MEDICAL SCIENCES  
NABH & NABL ACCREDITED ISO 9001:2015

REDEFINING  
CARE  
everyday  
in every way

# CLINIMED INSIGHTS

An Initiative By,

The Department of Clinical Pharmacy  
Amala Institute of Medical Sciences



# CONTENTS

## MED MINGLE

DENOSUMAB IN GCT OF BONE.....	04
SUMATRIPTAN INDUCED TAKOTSUBO CARDIOMYOPATHY; HEADACHE OF THE HEART.....	08
FDA WARNING REGARDING USE OF PROBIOTICS IN PRETERM INFANTS.....	09
IXCHIQ: FDA APPROVES FIRST VACCINE FOR CHIKUNGUNYA VIRUS.....	10
FDA APPROVES FIRST ORAL TREATMENT FOR POSTPARTUM DEPRESSION.....	10
FDA APPROVES NEW DRUG TO PREVENT RSV IN BABIES AND TODDLERS.....	10
DRUG SAFETY ALERTS-2023.....	11
NEW MOLECULES AT AMALA.....	12

## TOX TALK

DAPSONE INDUCED METHEMOGLOBINEMIA.....	13
SKIN LIGHTENING CREAM FOUND TO CAUSE MEMBRANOUS NEPHROPATHY.....	14

## CARING CHRONICLES

LIFESIGNS IMS.....	15
--------------------	----

## BRAINSTORM

CROSSWORD.....	16
----------------	----



# DIRECTOR'S MESSAGE



I am extremely happy to introduce the inaugural edition of '**CLINIMED INSIGHTS**', a newsletter proudly crafted by the Department of Clinical Pharmacy.

In recent years, the landscape of healthcare has evolved rapidly, presenting both challenges and opportunities. With advancements in medical science and technology, the complexity of patient cases has increased, requiring a multidisciplinary approach to management. In this context, the role of clinical pharmacists has expanded significantly.

Our focus is not only on medication management but also on promoting wellness, preventing medication-related problems, and optimising therapeutic outcomes.

Let us leverage technology to streamline processes, enhance communication, and improve medication safety. Let us also prioritise professional development, equipping ourselves with the knowledge and skills necessary to excel in our roles.


As pioneers in the field of healthcare, we recognize the importance of staying informed and connected within our dynamic healthcare landscape. The Newsletter will feature articles, case studies, and research highlights, drug updates, device updates, evidence-based practices, advancements in healthcare and serves as a platform for sharing insights, best practices, and updates in pharmacy practice, and driving innovation across our organisation.

I encourage each of you to actively engage with the Clinical Pharmacy Newsletter- '**CLINIMED INSIGHTS**', contribute your insights and expertise, and take advantage of the valuable resources and opportunities it offers. I extend my sincere appreciation to the editorial team for their dedication and hard work in bringing this initiative to fruition. Their passion for excellence and commitment to promoting professional growth and development are truly commendable. I look forward to the continued success and impact of this Newsletter.

Warm regards,

A handwritten signature in blue ink, appearing to read 'Julious Arakkal'.

**Fr. Julious Arakkal CMI**  
Director  
AIMS, Thirissur



# MED MINGLE



**Prof. Dr. Dominic Puthoor**  
Orthopaedic Oncologist  
AIMS, Thrissur

## DENOSUMAB IN GCT OF BONE

### Science wins over Evidence

Giant cell tumor (GCT) of bone is a benign, osteolytic neoplasm of bone. The receptor activator of NF- $\kappa$ B ligand (RANKL) pathway has been shown to play a key role in the pathogenesis of GCT. Development of a monoclonal antibody to RANKL, Denosumab, offered promise in the management of these patients. Denosumab was approved for marketing by the European Commission in May 2010. In June 2013, the FDA approved Denosumab for the treatment of adults and skeletally mature adolescents with giant cell tumor of bone that is unresectable or where resection would result in significant morbidity. Thereafter, lots of reports started coming from various parts of the world, to the extent that it was even termed as the wonder drug or golden bullet for Giant cell tumor of the bone. The situation had come to a stage where treatment of Giant cell tumor (GCT) of bone is going to be medical, and surgeons will not have any role in its treatment. The reason is, with Denosumab, GCT, which was destroying bone rapidly, is not only brought under control, but the areas already destroyed are replaced by healthy-looking bone. Histologically, there were also amazing changes; giant cells disappeared and there was extensive new bone formation.



Denosumab being an antibody to RANKL effectively prevents this recruitment process.

Soon, we understood that things are not that bright. Reports started coming showing inevitable recurrence on stopping the drug. In addition, the recurrence rate in cases treated by curettage after receiving Denosumab was found to be very high. Interestingly, one of the earlier reports of a higher rate of local recurrence is from India. To make things worse, there were isolated reports of malignant transformation in cases treated with Denosumab. A total of 11 cases of osteosarcoma developed in cases treated by Denosumab was reported till 2018.

What went wrong? If you analyze the pathophysiology of GCT and the scientific basis of the action of Denosumab, we can explain all these (Fig.1). Giant cell tumor of bone contains not only giant cell but stromal cells also. Stromal cells far outnumber giant cells and are found to be the real culprit behind the disease. It is the stromal cells that recruit monocytes from the circulation and convert them into osteoclast-like giant cells, which in turn produce lysis of the bone. This is achieved by overexpression of RANKL by the stromal cells. Under their influence, monocytes which express RANK undergo fusion to form multinucleated giant cells. This is comparable to extremist influencing and recruiting youngsters and making use of them for antisocial activities.

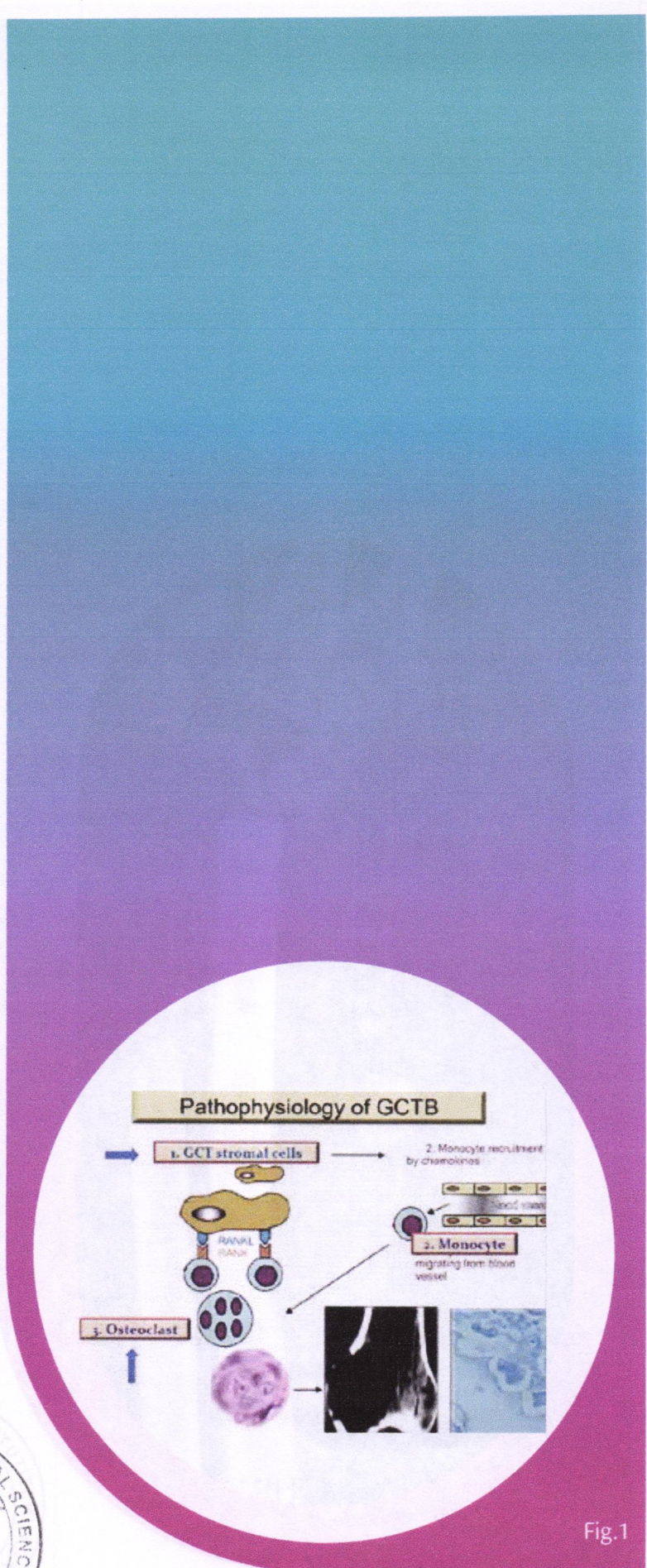



Fig.1

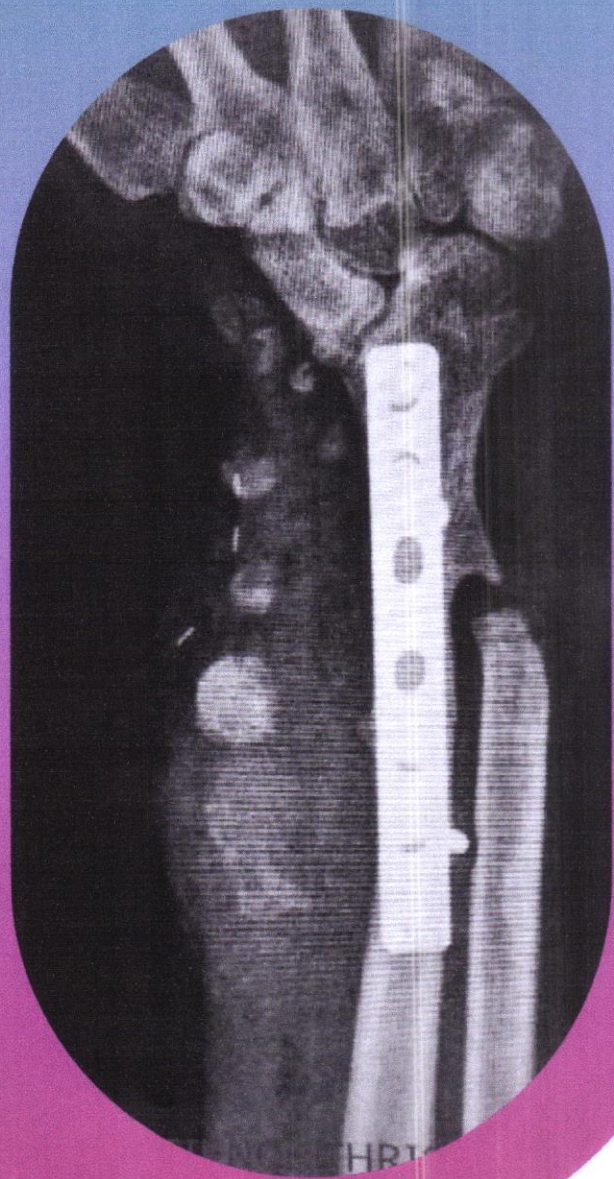

Fig.2

Denosumab, being an antibody to RANKL, effectively prevents this recruitment process. In that scenario, monocytes are converted into osteoblasts causing new bone formation. This explains the changes that occur in cases of GCT of bone treated with Denosumab. The fact remains that the real culprit, the big boss i.e. the stromal cell is not dealt with. Once Denosumab is withdrawn, stromal cells resume its recruitment. This explains recurrence of the lesion when the drug is stopped. Why there is an increased rate of recurrence in cases treated by curettage after getting Denosumab? The reason is, tumor cells (stromal cells) remain trapped between the various layers of bone which were formed by the action of Denosumab, making it difficult to assess the extent of the lesion. Even if you do a thorough extended curettage, tumor cells are likely to escape.

The scientific fact that Denosumab does not have action on stromal cells was known at the time when approval was given for its use in GCT of bone. But statistical evidence in various studies suppressed that scientific fact and gave it an aura of a magic drug. The cost of a single dose of Denosumab (120mg) at the time of its launch was 1200 U.S dollars. It took five years for the truth to become accepted. Looking back, most of the studies on the beneficial aspect of Denosumab were short-term studies and involved a small number of patients. Funding for most of the studies was from Amgen, Inc.



The situation is comparable to Solu-Medrol (Methylprednisolone Succinate) that was widely used for acute spinal cord injury. In spite of the fact it is a steroid, we were forced to use it for decades because of evidence.

Is there any role for Denosumab in the treatment of GCT of bone? Definitely there is. In the words of Dr. Manish Agarwal, Orthopedic Oncologist from Mumbai, after the peak of inflated expectations, trough of disillusionment and slope of enlightenment, we have come to a stage of Plateau of Productivity. Now the indications are well defined. There is no role for Denosumab in GCT of bone, if you are planning for curettage. There can be exceptions like sacrum where resection results in gross morbidity. Here pre-operative Denosumab makes the lesion less vascular. The drug can be continued post-operatively also. Now there is consensus regarding the use of Zoledronic acid instead of Denosumab post-operatively. How long it has to be given is a matter of concern.

The definite indication for the use of Denosumab is when we plan for resection of the tumor. This drug given preoperatively makes resections a lot easier. You get a nice hard shell from which you can separate the important neurovascular structures. Moreover, it helps to take out the tumor without tumor spillage, thus avoiding chances for local recurrence. This is a big advantage in bones like the spine, pelvis, proximal radius, and proximal fibula.

Yet another use of Denosumab I found very useful is when there is soft tissue recurrence. Fig.2 show, X-ray of a case of GCT lower radius treated by resection and ulnar transposition. Later he presented with soft tissue recurrence. Because of implant, MRI was not possible. After 3 doses of Denosumab, soft tissue recurrence became ossified and became visible in X-ray. Peri-operatively, a shell resembling an eggshell, developed in the periphery of the lesion made its removal easy and complete (Fig.3).

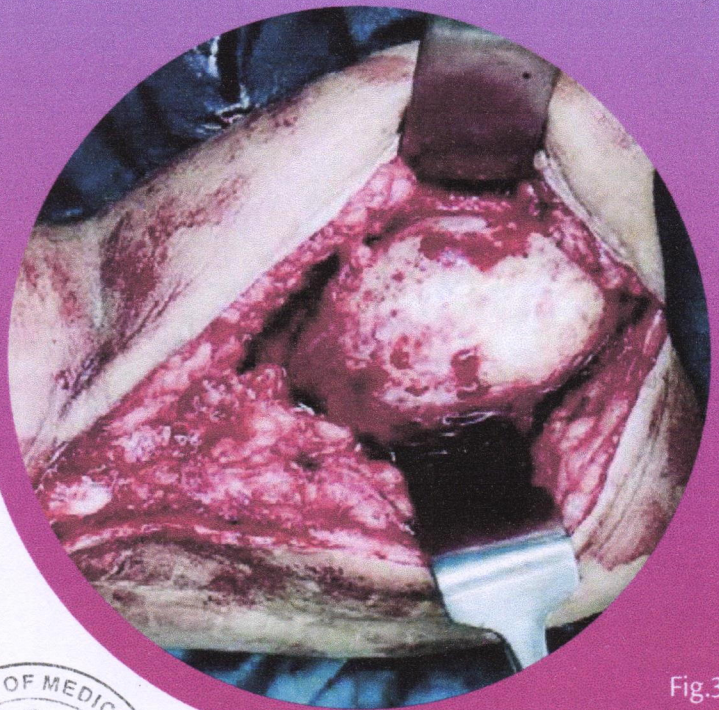

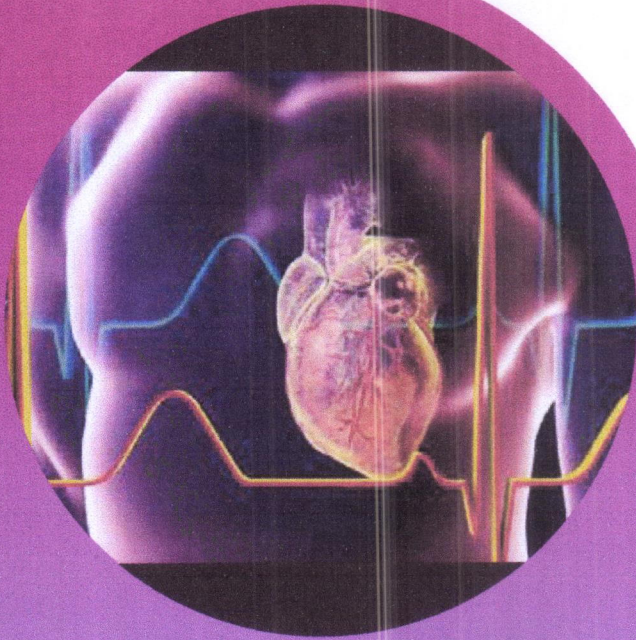


Fig.3





## SUMATRIPTAN INDUCED TAKOTSUBO CARDIOMYOPATHY; HEADACHE OF THE HEART

Takotsubo syndrome (TS) gets its name from the Japanese word for octopus pot, which is a tool used to trap octopus. This pot has a wide base and a slim opening, which resembles the gross appearance of a heart that has been affected by this disorder. Another name for this disorder is stress cardiomyopathy. This is because it often occurs in the setting of significant emotional distress, likely due to high concentrations of catecholamines. Indeed, this syndrome relates to the notion of “a broken heart,” as it is often seen in postmenopausal women who have experienced a significant stressor. This disease commonly presents in the absence of obstructive coronary artery disease (CAD). Recent evidence concerning the pathophysiology of TS suggests an interplay between neurologic and psychiatric factors. A leading hypothesis of TS postulates that catecholamine exerts a major role. There have been few cases that have reported TS secondary to triptan class administration, with sumatriptan as the most frequent drug of class to be mentioned.

This cardiomyopathy usually presents with classic signs and symptoms of acute coronary syndrome with dyspnea, chest pain, elevated cardiac biomarkers, and electrocardiographic changes suggestive of ischemia. It is most often characterized by the use of coronary angiography that demonstrates little to no significant obstructive atherosclerotic coronary vascular disease and classic apical ballooning seen on left ventriculography.




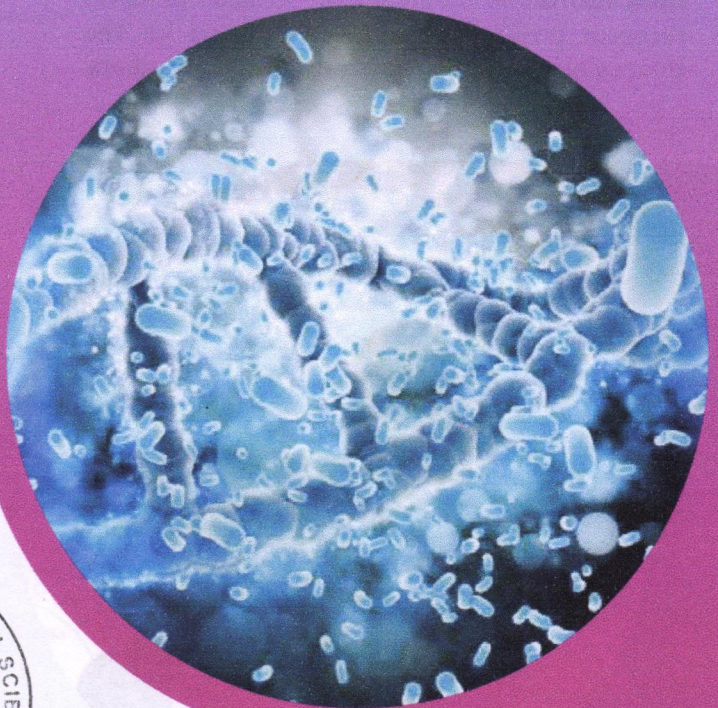
## FDA WARNING REGARDING USE OF PROBIOTICS IN PRETERM INFANTS

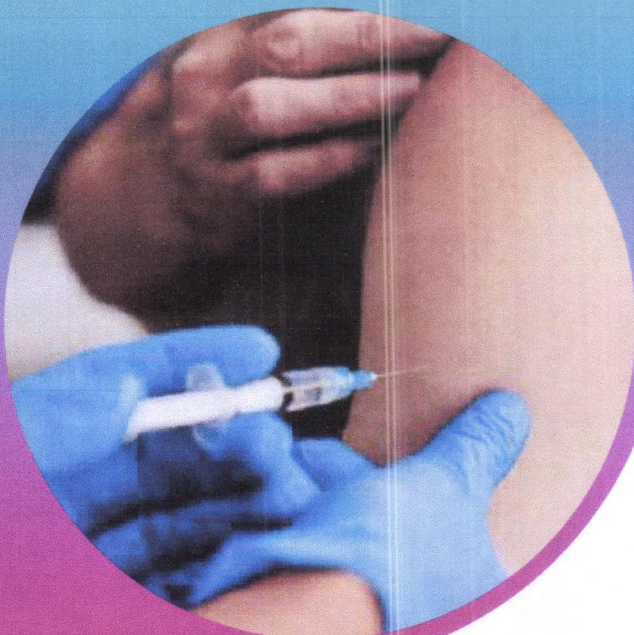
The FDA warns that preterm infants who are given probiotics are at risk of invasive, potentially fatal diseases caused by the bacteria or fungi contained in probiotics.

A preterm infant, birthweight <1000 g, who was administered a probiotic, Evivo with MCT Oil (Infinant Health), as part of in-hospital care, developed sepsis caused by the bacterium *Bifidobacterium longum* and subsequently died. Evivo with MCT Oil is a probiotic formulated to contain the live bacterium, bifid bacterium *longum* subsp. *Infantis*. The FDA is investigating the death of this preterm infant. Genomic sequencing data demonstrate the bacterium that caused sepsis in this infant was a genetic match to the bacteria contained in this probiotic.

The FDA is also reminding healthcare providers that FDA has not approved any probiotic product for use as a drug or biological product in infants.

Healthcare providers should be aware that these products have not undergone the FDA's rigorous premarket review evaluation for safety and effectiveness, nor have they been evaluated for compliance with the agency's rigorous manufacturing and testing standards for drugs and biological products, including testing for organisms.





## IXCHIQ: FDA APPROVES FIRST VACCINE FOR CHIKUNGUNYA VIRUS

**Vaccine:** IXCHIQ (Chikungunya Vaccine, Live)

**Manufacturer:** Valneva Austria GmbH

**Indication:** For the prevention of disease caused by Chikungunya virus (CHIKV) in individuals 18 years of age and older who are at high risk of exposure to chikungunya virus.

Ixchiq is administered as a single dose by injection into the muscle (approximately 0.5 mL dose). It contains a live, weakened version of the chikungunya virus and may cause symptoms in the vaccine recipient similar to those experienced by people who have chikungunya disease.

## FDA APPROVES FIRST ORAL TREATMENT FOR POSTPARTUM DEPRESSION

**Drug name:** ZURZUVAE (ZURANOLONE)

**Dosage:** Capsules 20 mg, 25 mg, and 30 mg

**Indications:** A neuroactive steroid GABA-A receptor positive modulator indicated for the treatment of postpartum depression in adults.




## FDA APPROVES NEW DRUG TO PREVENT RSV IN BABIES AND TODDLERS

**Drug name:** BEYFORTUS (NIRSEVIMAB-ALIP)

**Dosage:** Intramuscular Injection: 50 mg/0.5 ml in a single-dose pre-filled syringe.

**Indications:** A respiratory syncytial virus (RSV) F protein-directed fusion inhibitor indicated for the prevention of RSV lower respiratory tract disease.





## NOBEL PRIZE IN MEDICINE 2023

**Drew Weissman & Katalin Karikó**

Discoveries concerning nucleoside base modifications that enabled the development of effective mRNA vaccines against covid-19

## DRUG SAFETY ALERTS - 2023

SUSPECTED DRUG	ADR
Mefenamic acid	DRESS syndrome
Co-trimoxazole	Fixed drug eruption
Esomeperazole	Hyperprolactinaemia
Levonorgestrel	Deep Vein Thrombosis
Colistimethate	Bartter's like Syndrome
Levosulpride	Restless Leg Syndrome
Teneligliptin	Bullous Pemphigoid
Ziprasidone	DRESS syndrome



# NEW MOLECULES @ AMALA

## POLMACOXIB

**Pages 2 mg Capsule**  
(COX-2 Inhibitor)

### INDICATIONS:


Idiopathic (primary) Osteoarthritis of hip/knee

### DOSAGE AND ADMINISTRATION:

2 mg OD after a meal, should not exceed  
2mg/day.

### STORAGE:

Store below 30°C



## SOVATELTIDE

**Tyanzi 30µg per Vial**  
(Endothelin receptor agonist)

### INDICATIONS:

Cerebral ischemic stroke.

### DOSAGE AND ADMINISTRATION:

0.3 µg/kg/dose as IV bolus over one minute.  
3 doses/day at (3±1) hourly intervals.

1st dose should be initiated within 24 hours of  
stroke onset, after 1st day of treatment repeat  
doses should be administered on day 3 and 6.  
(Total 9 doses)

### STORAGE:

Store between 2°C-8 °C  
Do not store or refrigerate the reconstituted  
drug; use it immediately.

## VERICIGUAT

**Verquvo 2.5mg, 5 mg, 10 mg Tablet**  
(Soluble Guanylate Cyclase (sGC) Stimulator)

### INDICATIONS:


To reduce the risk of cardiovascular death and  
heart failure (HF) hospitalization following a  
hospitalization for heart failure or need for  
outpatient IV diuretics, in adults with  
symptomatic chronic HF and ejection fraction  
less than 45 %.

### DOSAGE AND ADMINISTRATION:

2.5 mg OD with food  
**Target maintenance dose:** 10 mg OD as  
tolerated by the patient.

### STORAGE:

Store below 30°C



# TOX TALK



Photograph showing urine colour that has turned green-blue after intravenous methylene blue.

## DAPSONE INDUCED METHEMOGLOBINEMIA

Dapsone is metabolized in the liver via CYP450 pathway to potent oxidants that are responsible for its adverse hematologic effects.

The diagnosis of methemoglobinemia is based on clinical symptoms and an elevated serum methemoglobin level. Cyanosis is usually seen at a serum methemoglobin level of 15%. Levels of 30-45% results in headache, tachycardia, weakness, and dizziness, while levels  $\geq 60\%$  result in cardiac arrhythmia, dyspnoea, seizures, and coma. Death typically occurs at levels  $\geq 70\%$ .

Unique features are the chocolate-brown color of the arterial blood samples, poor response to supplemental oxygenation, and presence of a saturation gap. Management primarily involves the withdrawal of the offending agent. For signs of hypoxia or methemoglobin levels  $\geq 30\%$ , administration of IV Methylene Blue at 1-2 mg/kg for 5 minutes is required. Patients should be warned that their urine and faeces may turn a blue-green colour.



## SKIN-LIGHTENING CREAM FOUND TO CAUSE MEMBRANOUS NEPHROPATHY

Last year (2023), patients started showing up before the nephrologists with a very rare form of Membranous Nephropathy. This intrigued the doctors and their probe showed that many of these patients had started using a fairness/skin-lightening cream containing heavy metal contents.

The 1st case was of a 14 -year-old girl with NELL1 MN positive MN syndrome. Later a couple of patients also presented with similar symptoms. With this, all patients who had similar symptoms were called. Of this, 8 people had started using a skin-lightening cream. The cream's label did not contain information about the product's manufacturers or its ingredients. The tests conducted revealed that the mercury and lead levels were 100 times higher than the permissible levels. The treatment mainly involves discontinuing the use such products, supportive care and chelation therapy.

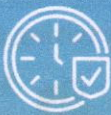

# CARING CHRONICLES

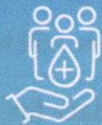

## Advanced Technology with Early Warning Score

Continuous Patient Monitoring




Timely Alert



Constant Care




Continuous Monitoring



## LIFESIGNS IMS

Wireless monitoring is transforming healthcare by enabling seamless, real-time tracking of patients' health data. With wearable devices and sensors, healthcare professionals can remotely monitor 8 vital signs, such as heart rate, blood pressure, and oxygen levels etc., without physical contact. This non-invasive approach enhances patient comfort and mobility while providing continuous insights into their health status. Wireless monitoring systems generate alerts for abnormalities or critical changes, allowing for timely interventions and proactive care.

# BRAIN STORM



## DOWNWARDS

1. Antidote for Tramadol.
2. FDA approved first oral treatment for Postpartum Depression.
3. Nobel Prize in medicine was awarded for the discoveries in the development of vaccine against which disease.
4. FDA approved vaccine for Chikungunya virus.
5. The protein present in highest concentration in blood is \_\_\_\_\_.

## INSTRUCTIONS

Use the clues to fill in the words above.  
Words can go across or down  
Letters are shared when the words intersect.  
Use the below link to take part in the puzzle.



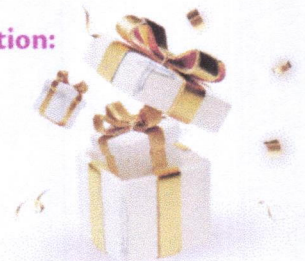Click QR Code for  BRAIN STORM PUZZLE QUIZ

## ACROSS

6. Stress Cardiomyopathy is another name for \_\_\_\_\_ Syndrome.
7. Intense fear of something.
8. Chemical name for laughing gas.
9. A type of Preeclampsia that causes hemolysis, elevated liver enzymes and low platelet.
10. Medical terminology for Headache.

Winner will be awarded with exciting gifts.

Last date for participation:  
May 10<sup>th</sup> 2024



## OUR PATRONS



**Fr. Julious Arakkal CMI**  
(Director)



**Fr. Deljo Puthoor CMI**  
(Joint Director)



**Fr. Jaison Mundanmany CMI**  
(Joint Director)



**Fr. Antony Mannummel CMI**  
(Associate Director)

## EDITORIAL TEAM



**Dr. Lejo Jacob A**  
(Pharmacy in charge)  
HOD Pharmacy & Clinical Pharmacy



**Dr. Dijoe Davis**  
(Patient Safety Officer)  
Dept. of Orthopedics



**Dr. Laween Lenos**  
(Clinical Pharmacist)  
Dept. of Clinical Pharmacy



**Dr. Irin K. Jose**  
(Clinical Pharmacist)  
Dept. of Clinical Pharmacy



**Dr. Ayana Mariya**  
(Clinical Pharmacist)  
Dept. of Clinical Pharmacy



**Dr. Filmie Fladento**  
(Clinical Pharmacist)  
Dept. of Clinical Pharmacy

Send your feedback: [clinicalpharmacy@amalaims.org](mailto:clinicalpharmacy@amalaims.org)



# Amala

INSTITUTE OF MEDICAL SCIENCES  
NABH & NABL ACCREDITED ISO 9001: 2015

REDEFINING  
CARE  
everyday  
in every way

*Betsy*

Dr. BETSY THOMAS  
MD, FRCOG, DNB, MICOG  
PRINCIPAL

AMALA INSTITUTE OF MEDICAL SCIENCES  
AMALA NAGAR, THRISSUR-680 555

Amala Institute of Medical Sciences | Amala Nagar PO, Thrissur, Kerala. | Ph: 0487 2304000 [www.amalaaims.org](http://www.amalaaims.org) | Follow us on 