

International Journal of Clinical Obstetrics and Gynaecology

ISSN (P): 2522-6614
ISSN (F): 2522-6622
© Gynaecology Journal
www.gynaecologyjournal.com
2023; 7(5): 101-105
Received: 10-09-2023
Accepted: 14-10-2023

Dr. Prameela Menon
Professor, Department of
Obstetrics and Gynaecology,
Amala Institute of Medical
Sciences, Thrissur, Kerala, India

Dr. Chithra Govind
Junior Resident, Department of
Obstetrics and Gynaecology,
Amala Institute of Medical
Sciences, Thrissur, Kerala, India

Corresponding Author:
Dr. Chithra Govind
Junior Resident, Department of
Obstetrics and Gynecology, Amala
Institute of Medical Sciences,
Thrissur, Kerala, India

Safety and efficacy of the trans obturator tape for stress urinary incontinence

Dr. Prameela Menon and Dr. Chithra Govind

DOI: <https://doi.org/10.33545/gynae.2023.v7.i6b.1406>

Abstract

Background: Among young adults and middle aged, stress urinary incontinence (SUI) is reported approximately in 25% of women and its prevalence increases further with the increase in age. Following an increasing number of women reporting complications after mesh surgery, it was announced that all mid-urethral slings for SUI would be suspended in England for at least nine months.

Methods: A retrospective observational study on 35 patients who underwent trans obturator tape (TOT) with polypropylene mesh, to assess the safety and efficacy of the procedure for the surgical treatment of female stress urinary incontinence with the help of a structured questionnaire.

Results: The mean age of women in our study was 49yrs. 97% of the study population were multiparous women and 85.7% of them had all vaginal deliveries and the rest had undergone cesarean section. Majority of the patients – 60% presented with mixed incontinence while 40% had pure stress incontinence. An intra-op complication in the form of bladder injury was noted in one patient. We could find significant differences in the incidence of post-op complications like mesh erosion and recurrent UTI compared to corresponding foreign studies.

Conclusion: Our study confirms that TOT is a safe procedure in the short and long term with very few intraoperative, early, and late post-operative complications. TOT is an effective and successful procedure with 62.9% of cured patients and 37.1% of improved patients during a five-year follow-up in our population. However, large multicentric studies are recommended to come to a robust conclusion regarding its long-term safety and efficacy.

Keywords: SUI, Trans-obturator tape, efficacy, mesh erosion, mesh complications

Introduction

Mrs. JK, a 42 year old high school teacher was in despair as she always had urine leak whenever she sneezed. Being allergic to chalk dust made her every day a nightmare, right from the 1st hour of class. She is completely relieved of her symptoms after the procedure and is extremely thankful for it. Now she is more confident than ever.

Urinary incontinence is a common, distressing condition that affects women of all ages and can have a profound impact on quality of life [1]. Among young adults and middle-aged, SUI is reported in approximately 25% of women and its prevalence increases further with the increase in age [2]. More than 200 types of procedures have been described in the literature for the treatment of stress incontinence [3]. Trans obturator Tape (TOT) is a minimally invasive procedure designed by Delorme (2001) and modified by De Leval (2003) to support the urethra as a hammock and has been widely accepted as the primary surgical treatment of SUI [2].

Following an increasing number of women reporting complications after mesh surgery including debilitating pain, infection, inflammation, loss of sex life, and mobility problems, on 10th July 2018, it was announced that all mid-urethral slings (MUS – known commonly and defined as “tapes”) for stress urinary incontinence (SUI) would be suspended (“paused”) in England for at least nine months [4]. Hence we conducted a study to assess the long-term outcomes and adverse effects of the trans obturator tape inside-out technique for patients with SUI in our population.

AIM

To assess the safety and efficacy of the trans obturator tape (TOT) for the surgical treatment of female stress urinary incontinence

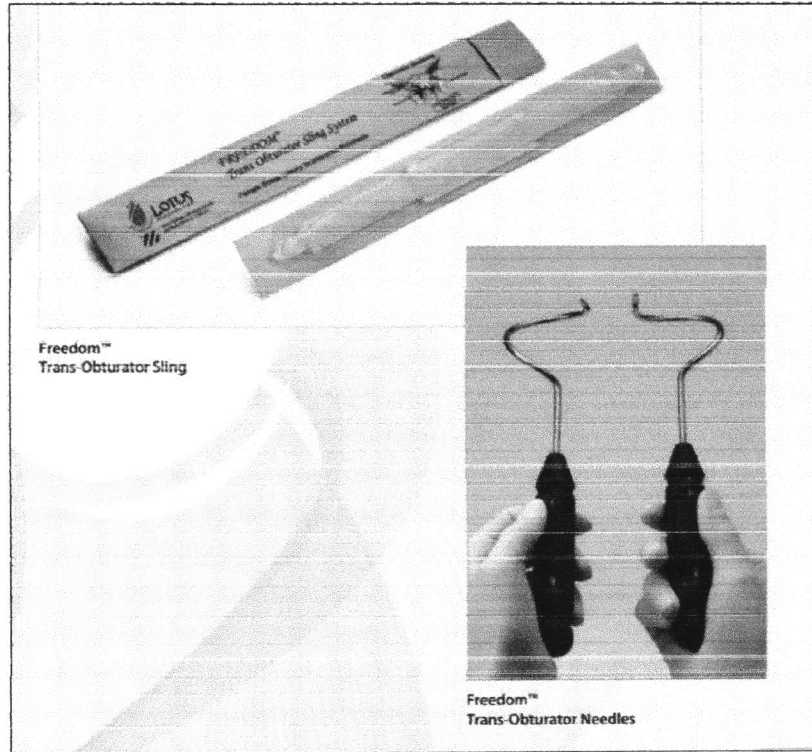


Objectives


- To assess the improvement in quality of life.
- To look for intra-op complications like bleeding, bladder injury, and post-op complications including mesh-related complications, infections, urinary retention, dyspareunia, and recurrence over a period of 5 years.

Materials and Methods

A retrospective observational study on 35 patients who underwent TOT with polypropylene mesh (LOTUS - FREEDOM) inside-out technique from 2012 to 2017 under the gynaecology and urology departments of Amala Institute of Medical Sciences, Thrissur were approached with a definitive questionnaire and responses were recorded and analysed.



Product Detail

Sling:	Monofilament Dia. mm (in)	Typical Pore Size mm (in)	Burst Strength kpa (psi)	Break Strength N/2.5 cm (lbs/in)		Break Elongation (%)		Thick mm (in)	WT. g/m ² (oz/yd ²)
				MD	CMD	MD	CMD		
	0.15 (.006)	1.3 x 1.0 (.051 x .039)	1172 (162)	526 (118)	492 (111)	107	175	0.59 (.023)	100 (2.9)

The diagrams illustrate the surgical steps for Transobturator tape (TOT) placement. Diagram A shows the initial incision and dissection. Diagram B shows the identification and dissection of the obturator foramen. Diagram C shows the insertion of the tape through the obturator foramen. Diagram D shows the final placement and fixation of the tape.

Fig 3A to D: Transobturator tape (TOT) surgical steps



Questionnaire

Age; Parity; Co-morbidities; Presenting symptoms; Prior medical/surgical treatment; Any concomitant procedures; Duration of hospital stay; Intra-op complications; Immediate

post-op complications; Late post-op complications; Time taken for relief; Effect on quality of life, and the recurrence of symptoms.

Table I: Characteristics of patients, symptomatology and management details of trans obturator tape procedure

S. No:	Parameter	Number	Range	Mean	SD	Percentage
1	Age (years)		32-66	48.60	7.267	
2	Parity		1-5			97.1 (>=2)
3	Past Obstetric History					
	NVD	30				85.7
	Cesarean section	5				14.3
4	Symptoms					
	SUI	14				40
	Mixed	21				60
5	Medical treatment	9				25.7
6	Concomitant procedure	8				32.9
7	Intra-op complications	1				2.8
8	Post-operative hospital stay		3-7	3.7	1.28	

Results and Analysis

The mean age of the population studied was 49 years and majority of them were multiparous (>97%). Among the 35 patients studied, 30 had undergone all vaginal deliveries, while 5 were previous CS candidates. Majority of the patients i.e; 60%, had presented with mixed incontinence and the rest had only stress urinary incontinence. 9 patients gave a history of medical treatment prior to the procedure and 8 patients had undergone simultaneous reconstructive surgeries like cystocele repair or vaginal hysterectomy.

Only 1 patient developed an intra-operative complication, in the form of a bladder injury for which she underwent cystoscopy and repair simultaneously. The average hospital stay was 3.7 days.

Table 2: Time taken for initial and complete relief after TOT (% of patients)

Time	initial	Complete
Immediate	85.7	85.7
2 Week	5.7	5.7
1 Month	8.5	8.5

Out of the 35 patients studied, 85.7% patients received both initial and complete relief from symptoms immediately following the procedure and 5.7% had relief within a period of 2 weeks. But in 8.5% of patients, it took 1 month to show the result.

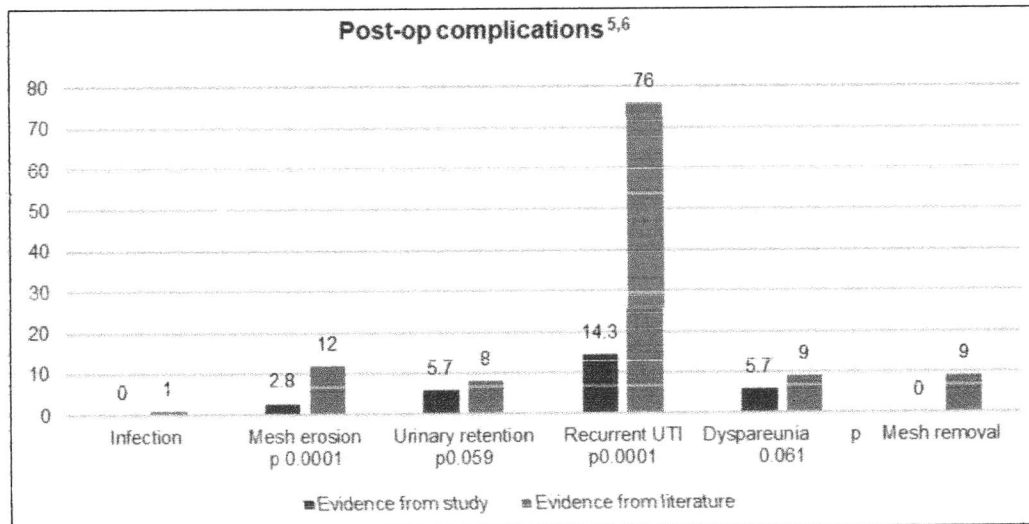


Fig I: Post-op complications

The incidence of all the post-operative complications including infections, mesh erosion, urinary retention, recurrent urinary tract infections, and dyspareunia leading to mesh removal were less compared to corresponding foreign studies, and a significant difference was noted in the incidence of mesh erosion and

recurrent UTI with p value 0.0001. (After z test for significance $p < 0.05$ being significant).

All patients lead a symptom-free life for one year. 5.7% had recurrence at the end of 1 year and 37% of patients had recurrence by the end of 5 years.



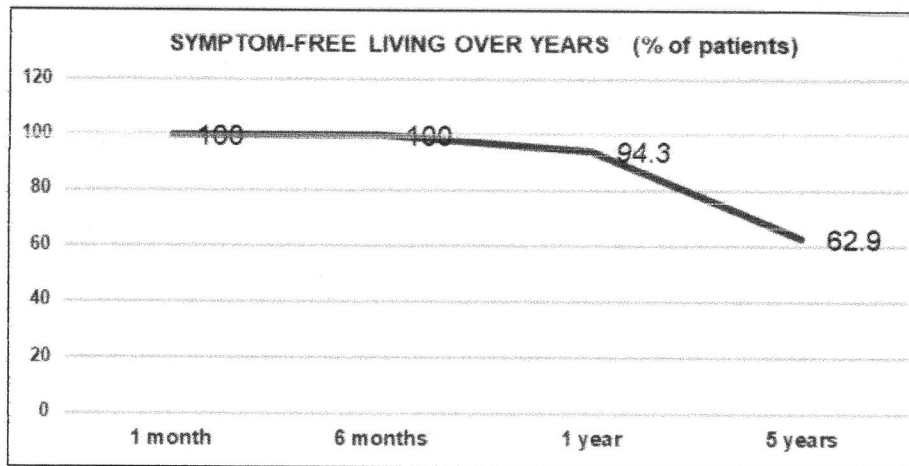


Fig 2: Symptom-free living

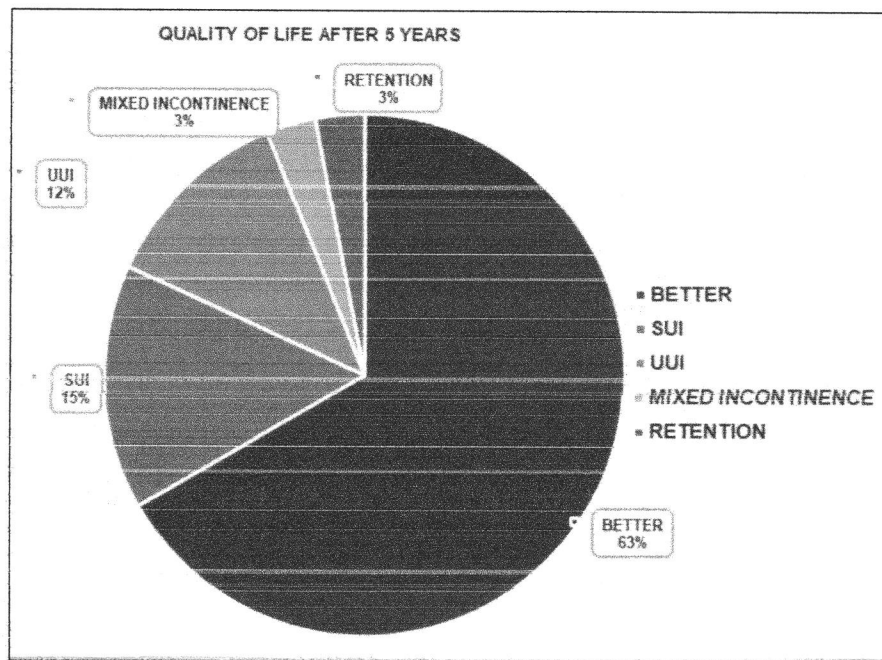


Fig 3: Quality of life after 5 years

Around 63% of patients lead a symptom-free life after 5 years but the rest had a recurrence in the form of stress incontinence (15%), urge incontinence (12%), mixed incontinence, and urinary retention (3%) respectively.

Discussions

Our study confirms that TOT is a safe procedure in the short and long term with very few intraoperative, early, and late postoperative complications. The incidence of mesh erosion and recurrent urinary tract infection is significantly less compared to foreign studies. TOT is an effective and successful procedure with 62.9% of cured patients and 37.1% of improved patients during a five-year follow-up in our population. However, large multicentric studies are recommended to come to a robust conclusion regarding its long-term safety and efficacy.

Conflict of Interest


Not available

Financial Support

Not available

References

1. Church E, Hanna L. Safety and efficacy of the transobturator tape for stress urinary incontinence: short-term and medium-term results of 125 patients demonstrate a procedure-related learning curve. *Gynecol Surg*. 2010;7:31-37. DOI: 10.1007/s10397-009-0532-0.
2. Gandhi A, Tank P, Purandare A, editors. FOGSI's Postgraduate Gynaecology Textbook 1st edition Vol 2. Urogynecology. New Delhi: Jaypee Brothers; 2022. p. 749-752.
3. Jones HW, Rock JA, editors. Te Linde's Operative Gynecology Eleventh Edition. Stress Urinary Incontinence. September 2014; p. 915.
4. Update on the Independent Medicines and Medical Devices Safety Review: Written statement - HCWS841. Published July 2018. Available at: <https://www.parliament.uk/business/publications/written-questions-answers-statements/written-statement/Commons/2018-07-10/HCWS841>.
5. NICE guideline Urinary incontinence and pelvic organ prolapse in women: Management. Published: 2 April 2019; www.nice.org.uk/guidance/ng123.



6. Mesh Oversight Group Report Version No: 1. First published: July 2017. Prepared by: Maternity and Women's Health Team, NHS England, with British Society of Urogynecology (BSUG); British Association of Urological Surgeons (BAUS); the Royal College of Obstetricians and Gynecologists (RCOG), and the Medicines and Healthcare products Regulatory Agency (MHRA), National Institute for Health and Care Excellence (NICE), the Department of Health (DH).

How to Cite This Article

Menon P, Govind C. Safety and efficacy of the trans obturator tape for stress urinary incontinence. International Journal of Clinical Obstetrics and Gynaecology. 2023;7(5):101-105.

Creative Commons (CC) License

This is an open access journal, and articles are distributed under the terms of the Creative Commons Attribution-Non-Commercial-Share Alike 4.0 International (CC BY-NC-SA 4.0) License, which allows others to remix, tweak, and build upon the work non-commercially, as long as appropriate credit is given and the new creations are licensed under the identical terms.



Betsy

Dr. BETSY THOMAS
MD, FRCOG, DNB, MICOG
PRINCIPAL
AMALA INSTITUTE OF MEDICAL SCIENCES
AMALA NAGAR, THRISSUR-680 555